

### Gluteal Sciatic block

The sciatic nerve may also be identified after it leaves the pelvis as it runs medial to the hip joint superficial to quadratus femoris and deep to gluteus maximus

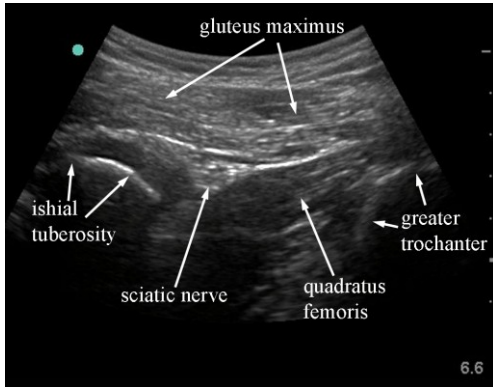


Fig 3.29 Sonogram of the sciatic nerve at the level of the ischial tuberosity in the buttock.

The nerve is identified lateral and deep to the bony reflection of the ischial tuberosity and superficial to the quadratus femoris muscle.

Often a lower frequency curvilinear probe is more useful to identify the nerve at this level both for increased field of view and penetration. The nerve may be approached both in plane and out of plane the out of plane approach being used by some for catheter placement.

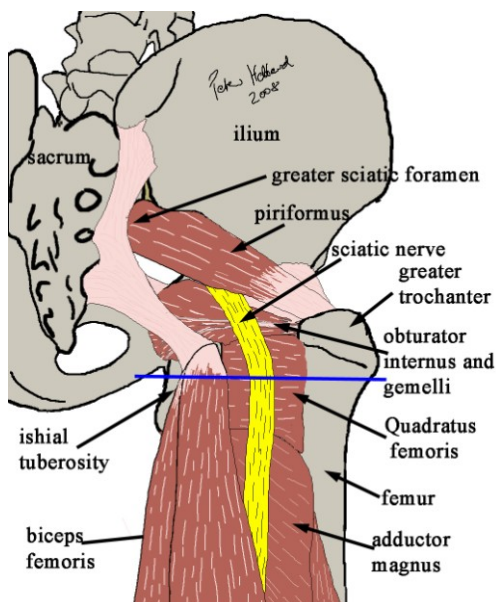


Fig 3.30 major relations of the sciatic nerve under the gluteus maximus muscle from posterior. Line indicates plane of scan in fig 3.28

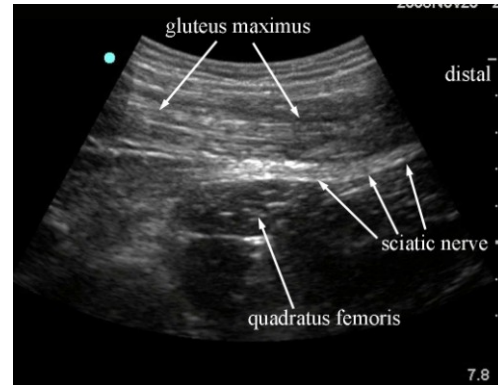


Fig 3.31 sonogram of long axis view of the sciatic nerve passing posterior to quadratus femoris.

The nerve may also be identified more proximally as it exits the pelvis via the greater sciatic foramen coming from deep to the piriformis muscle. The sciatic notch is best identified with a curvilinear probe starting obliquely over the alar of the ilium and scanning medially and inferiorly towards the sciatic foramen. The piriformis muscle is seen appearing in long axis with the sciatic nerve coming over the deep surface and emerging into the buttock.

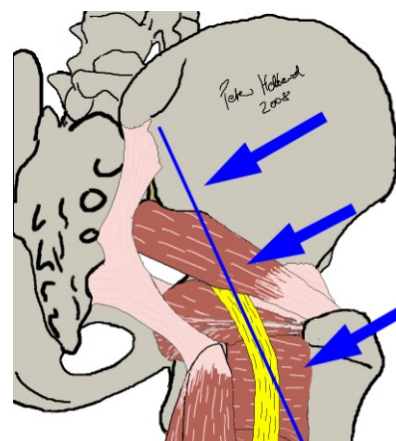


Fig 3.32 plane of scan and direction of sliding to identify the sciatic nerve in long axis emerging from deep to piriformis muscle

## Ultrasound Guided Procedures in Anaesthesia

Hebbard, Barrington & Royse

www.heartweb.com.au

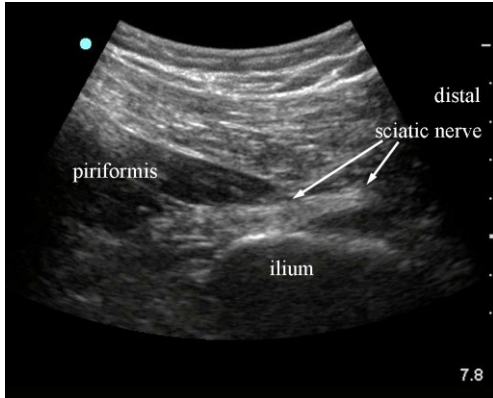


Fig 3.33 sonogram in plane of fig 3.31 showing sciatic nerve in long axis

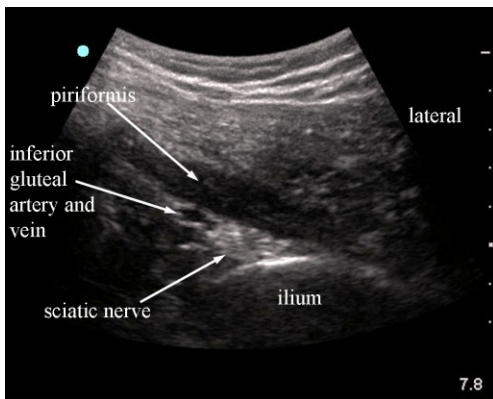


Fig 3.34 short axis view of sciatic nerve deep to piriformis. Note the superior gluteal vessels.

In describing this ultrasound guided procedure it has been assumed that attention has been paid to appropriate location, personnel, sterility, preparation, doses and technique necessary for the safe conduct of major nerve blocks and other procedures. These medical procedures should not be attempted without suitable qualifications

### Acknowledgements

Thanks go to the Ecole Polytechnique Federale de Lausanne for the excellent anatomical slices that can be obtained from the data set of the Visible Human Project via their website at <http://visiblehuman.epfl.ch/>