

## **Anterior Sciatic block**

The sciatic nerve may be imaged in the mid thigh from anterior using a curvilinear probe. The nerve is often quite prominent lying posterior to adductor magnus and strongly anisotropic. A block may be performed perpendicularly in plane with the hip flexed and externally rotated to come from the medial thigh. The obturator nerve, either side of adductor brevis, and the femoral vessels should be avoided if coming from in plane close to the transducer or across plane.

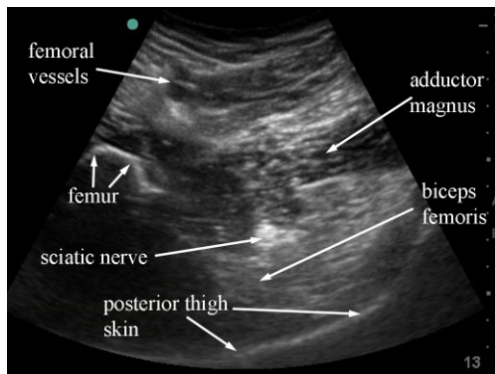


Fig 3.35 sonogram of a transverse scan of the anterior thigh showing the sciatic nerve deep to adductor magnus.

In describing this ultrasound guided procedure it has been assumed that attention has been paid to appropriate location, personnel, sterility, preparation, doses and technique necessary for the safe conduct of major nerve blocks and other procedures. These medical procedures should not be attempted without suitable qualifications

## **Acknowledgements**

Thanks go to the Ecole Polytechnique Federale de Lausanne for the excellent anatomical slices that can be obtained from the data set of the Visible Human Project via their website at <http://visiblehuman.epfl.ch/>