

Obturator nerve block

The obturator nerve emerges into the anterior thigh through the obturator foramen deep to pectineus and then divides into an anterior and posterior branch around adductor brevis.

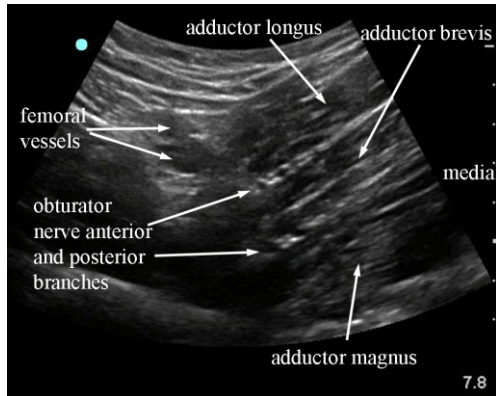


Fig 3.36 sonogram of transverse scan of proximal thigh from anterior. The two branches of the obturator nerve are apparent either side of adductor brevis.

The nerve is typically very flattened and most readily identified either side of the adductor brevis in short axis with accompanying vessels.

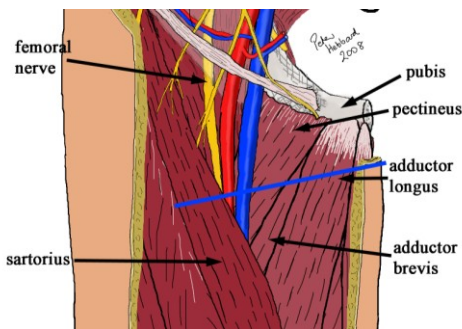


Fig 3.37 plane of scanning for obturator block as in fig 3.36

The nerve is most readily approached using an across plane technique and aiming to fill the fascial space either side of adductor brevis with local anaesthetic without passing through the nerve.

In describing this ultrasound guided procedure it has been assumed that attention has been paid to appropriate location, personnel, sterility, preparation, doses and technique necessary for the safe conduct of major nerve blocks and other procedures. These medical procedures should not be attempted without suitable qualifications

Acknowledgements

Thanks go to the Ecole Polytechnique Federale de Lausanne for the excellent anatomical slices that can be obtained from the data set of the Visible Human Project via their website at <http://visiblehuman.epfl.ch/>